

**Case Report**

# Accessory Cavitated Uterine Mass (ACUM) - A Rare Cause of Pelvic Pain in Young Women

**Brinderjeet Kaur***Department of Obstetrics and Gynecology, Santokba Durlabhji Memorial Hospital and Research Center, India***Received:** September 30, 2022; **Published:** October 12, 2022**\*Corresponding author:** Brinderjeet Kaur, Department of Obstetrics and Gynecology, Santokba Durlabhji Memorial Hospital and Research Center, India**Copyright:** © 2022 Brinderjeet Kaur, This is an open-access article distributed under the terms of the Creative Commons Attribution License, which permits unrestricted use, distribution, and reproduction in any medium, provided the original author and source are credited.

## Abstract

**Background:** A rare Mullerian anomaly may be a cause of severe dysmenorrhea and recurrent pelvic pain not responding to medical management in young women.

**Materials and Methods:** We present a case report of a rare anomaly, accessory cavitated uterine mass (ACUM) / Uterine like mass managed successfully by laparoscopic resection of the uterine mass and suturing of the myometrial defect on uterus at our institute SDMH.

**Results:** ACUM or Accessory cavitated uterine mass earlier reported as juvenile cystic adenomyoma represent a rare, newly recognized Mullerian anomaly observed in young females suffering from severe dysmenorrhea and recurrent pelvic pain. The diagnosis is made when an isolated extra-cavitated uterine mass is seen in an otherwise normal appearing uterus with unremarkable endometrial lumen and adnexal structures. Laparoscopic excision of the mass remains the mainstay of treatment.

**Conclusion:** Awareness about the entity, early diagnosis and laparoscopic excision of the mass brings instant relief to the young woman.

## Keywords

Pelvic Pain, Dysmenorrhea, Accessory and Cavitated Uterine Mass; Juvenile Cystic Adenomyoma; Mullerian Anomalies; Uterus-like Mass.

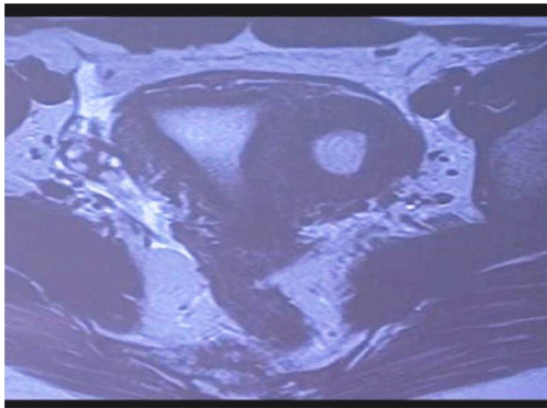
## Introduction

Accessory cavitated uterine mass (ACUM) is a rare developmental mullerian anomaly that is characterized by presence of accessory cavity in uterus in an otherwise normal uterus seen in young female presenting with chronic pelvic pain and dysmenorrhea [1-6].

## Case report

We report a case of 17-year-old girl who presented to the department of Obstetrics & Gynecology with complaints of recurrent abdominal pain in left iliac fossa since two years. She took medical treatment elsewhere with non-steroidal anti-inflammatory drugs (NSAIDS) and oral

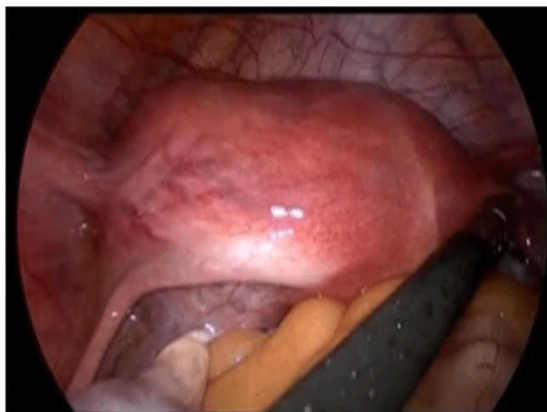
contraceptive pills (OCP) for the last few months but did not respond. She attained menarche at the age of 14 years thereafter her menstrual cycles were regular with normal flow. The general physical examination was unremarkable. The history revealed that she underwent ultrasonography examination multiple times before presenting to our institute. The previous ultrasonography reports document different pathologies like ovarian torsion, degenerated myoma and endometriosis. We decided to get a MRI scan done that showed normal uterus with well defined, non communicating cavitated mass measuring 3 x 4 cm along left anterior uterine wall just below the insertion of round ligament was seen. The cavity lining was hyper intense on T2 with hemorrhagic contents that differentiated the



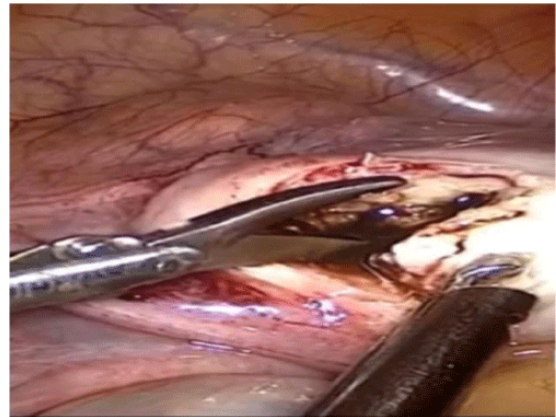
**Figure 1:** Coronal T2W image showing a cavitated mass attached just below the round ligament containing hypointense contents suggestive of blood products and lined by T2–hyperintense endometrium. Normal shaped uterine cavity with both cornua attached normally. Bilaterally ovaries are normal and separate from mass.

mass from fibroid, adenomyoma as they do not show up hyper intense T2 as they lack endothelial lining (Figure 1). The junctional zone of the cavity was thickened (13mm) with indistinct endomyometrial interface. The uterine cavity perse was normal with normal coruna, ovaries and fallopian tubes without any evidence of endometrotic deposits.

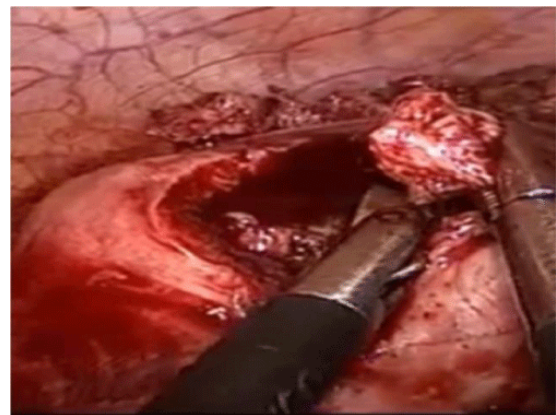
A provisional diagnosis of ACUM was made and the patient was taken for diagnostic Laparoscopy. For diagnostic laparoscopy after creating pneumoperitoneum, 10 mm supra umbilical port was inserted using Verre's needle along with two 5 mm left accessory side ports. The laparoscopy showed a broad based uterus having mass attached to left anterior uterine wall below the attachment of round ligament. Both ovaries and fallopian tubes appeared normal without any evidence of endometriosis (Figure 2). The patient being an unmarried female hence hysterosalpingography (HCG) was not done. Laparoscopic resection of ACUM was planned immediately after diagnostic laparoscopy confirmed the previous MRI findings. Vasopressin (20 units in 200 ml normal saline)



**Figure 2:** Laparoscopic view as seen on introduction of endoscopy



**Figure 3:** Laparoscopic resection of the ACUM



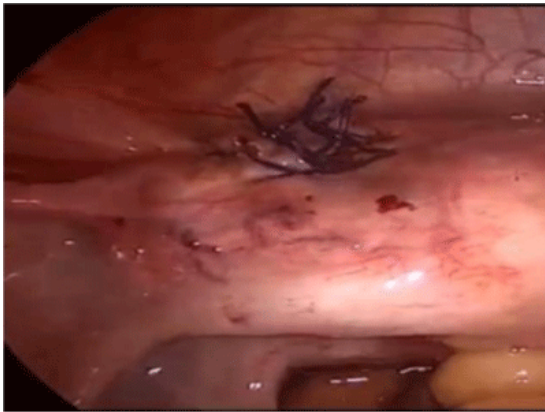**Figure 4:** Laparoscopic view of an incision made over the anterior wall of the mass and 10 ml of chocolate-colored fluid was drained

was injected with a needle along the ACUM – uterine serosal interphase in the adjacent myometrium to achieve homeostasis (Figure 3).

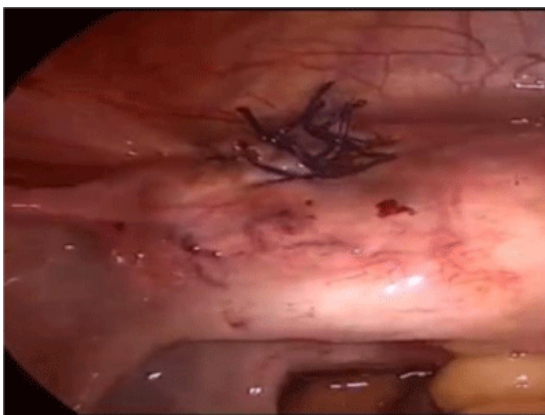ACUM seros was incised using scissors with an incision over anterior wall of mass with subsequent drainage of 10 ml of chocolate colored fluid. We performed Enucleation in a circumferential manner along the ACUM and uterine myometrial interphase using scissors (Figure 4). After resection homeostasis was achieved and uterine defect was closed in 2 layers using 1-0 vicryl (Figure 5). The resected tissue was sent for detailed histopathological examination. The microscopy was indicative of uterine mass comprising of endometrial glands and stroma (Figure 6).

## Discussion

The first case of such uterine mass was reported by Cozzutto in 1981 [6]. But since thereafter there has been increased awareness among clinicians and it is been diagnosed more frequently. ACUM is a rare congenital mullerian anomaly commonly seen in young nulliparous women presenting with dysmennohœa and infertility. The diagnosis of this anomaly is challenging as it confused with several gynecological disorders including non



**Figure 5:** Laparoscopic view of closing the uterine defect in at least 2 layers using a 1-0 vicryl



**Figure 6:** Hematoxylin & Eosin stained tissue section (10x)

communicating rudimentary uterine horn, true cavitated adenomyoma and generating fibroid. It is characterized by the presence of normal uterus with duplication and persistence of ductal mullerian tissue at the insertion of the round ligament due dysfunction of gubernaculum [5]. It is important that the gynecologist should have high index of suspicion for ACUM where young female complaints of dysmenorrhoea and or chronic pelvic pain. The mass lesion in our case was highly suggestive of ACUM considering younger age of presentation with classical complaints of dysmenorrhoea, pelvic pain and latter MRI findings showing normal uterus and absence of endometriotic features [3]. ACUM arises due to duplication of ductal mullerian tissue due to dysfunctioning gubernaculum and in some cases associated gastrointestinal and genitourinary anomalies are also observed. Apart from uterus it may also be seen in ovary, broad ligament, small bowel mesentery and appendix [7].

**Acien et al described ACUM with following diagnostic criteria:**

- An isolated accessory cavitated mass usually located under round ligament
- Normal uterus, fallopian tubes, and ovaries

- Surgical evidence of excised mass and pathological examination
- The lining of accessory cavity is by endometrial epithelium with glands and stroma
- Chocolate brown colored fluid content
- No adenomyosis

ACUM was previously known as Juvenile cystic adenomyosis which is a rare variant of adenomyosis having large hemorrhagic cyst with an ectopic endometrial glands occurring in a young female with dysmenorrhea and pelvic pain that is resistant to medical therapy. There are closely related pathologies that present with dysmenorrhea. Uterine mass for adenomyosis may cause dysmenorrhea in women in their forties. Generally adenomyosis are solid and its cystic spaces are less than 0.5 cm in diameter. Juvenile cystic adenomyoma is a solitary myometrial cyst is generally more than 1 cm that is independent of uterus and is lined by hypertrophied endometrium, it presents with dysmenorrhea in young female of less than 30 years of age as a variant of adenomyosis [8]. Complete EN bloc resection with sufficient margin is to be done as treatment. In our case there was absence of adenomyotic Lesion and complete resection of mass along with endometrial lining brought symptomatic relief to the patient [9]. Laparoscopic surgery is the best treatment and anterior approach is preferred over posterior one as it carries lower risk of hemorrhage from ascending branch of uterine artery [10, 11]. The initial investigation is done for evaluation of pelvic pain is ultrasonography USG. On USG it is seen as solid cystic mass with the uterus with clear separate visualization from ovaries and fallopian tubes. HSG has limited value in making concrete diagnosis and is only helpful to rule out mullerian anomalies. MRI is investigation of choice which is preferred over HSG specially in young unmarried female [3]. MRI enables visualization of pelvic anatomy, the cavitated mass along with the presence of hemorrhage contains uterus. MRI also adds in differentiating ACUM from adenomyosis and pelvic endometriosis. After resection the excised mass was sent for complete histopathologic examination. Grossly, it consisted of multiple grey white soft tissue pieces measuring in total 3.5 X 2.5 X 2 cm with microscopic examination revealing endometrial glands and stroma. Table 1 shows a helpful mnemonic for quick recap of this congenital anomaly characterized by three – clinical features, pathology, investigations, treatment options and differential diagnosis- three's anomaly.

## Conclusion

ACUM or uterus in uterus is a very rare congenital disease that may present with incapacitating pain. For practicing gynecologists it is prudent to keep ACUM in differential diagnosis in young girl with severe dysmenorrhea that is refractory to medical treatment. The extreme pain adds to



**Table 1:** ACUM the 3 S of sailent features

Accessory and Cavitated Uterine Mass (ACUM) 3 S				
Clinical Features	Pathology	Investigations	Treatment	Differentials
Dysmenorrhoea	Congenital anomaly	USG	Laparoscopic resection	Non communicating rudimentary horn
Pelvic pain	Heterotopia	HSG	USG guided radio ablation	True cavitated adenomyoma
Infertility	Metaplasia	MRI	Single incision monopolar cautery	Degenerated fibroid

the severe mental stress therefore awareness at the level of gynecologist and radiologist is essential as accurate diagnosis and surgical management gives complete cure and improves immensely the quality of life.

### Sources of funding

No

### Conflict of interest

No

### References

- Kriplani A, Mahey R, Agarwal N, Bhatla N, Yadav R, Singh MK. Laparoscopic management of juvenile cystic adenomyoma: Four cases. *J Minim Invasive Gynecol* 2011; 18: 343-348.
- Akar ME, Leezer KH, Yalcinkaya TM. Robot-assisted laparoscopic management of a case with juvenile cystic adenomyoma. *Fertil Steril* 2010; 94: 55-56.
- Jain N, Verma R. Imaging diagnosis of accessory and cavitated uterine mass, a rare mullerian anomaly. *Indian Journal of Radiology and Imaging* 2014; 24: 178-181.
- The American Fertility Society classifications of adnexal adhesions, distal tubal occlusion, tubal occlusion secondary to tubal ligation, tubal pregnancies, müllerian anomalies and intrauterine adhesions. *Fertil Steril* 1988; 49: 944-955.
- Acién P, Sánchez del Campo F, Mayol MJ, Acién M. The female gubernaculum: Role in the embryology and development of the genital tract and in the possible genesis of malformations. *Eur J Obstet Gynecol Reprod Biol* 2011; 159: 426-432.
- Cozzutto C. Uterus-like mass replacing ovary: Report of a new entity. *Arch Pathol Lab Med* 1981; 105: 508-511.
- Takeuchi H, Kitade M, Kikuchi I, Kumakiri J, Kuroda K, Jinushi M. Diagnosis, laparoscopic management, and histopathologic findings of juvenile cysticadenomyoma: A review of nine cases. *Fertil Steril* 2010; 94: 862-868.
- Jain N, Goel S. Cystic Adenomyoma simulates uterine malformation: A Diagnostic dilemma: Case report of two unusual cases. *J Hum Reprod Sci* 2012; 5: 285-288.
- Khati NJ, Frazier AA, Brindle KA. The unicornuate uterus and its variants: Clinical Presentation, imaging findings, and associated complications. *J Ultrasound Med* 2012; 31: 319-331.
- Bedaiwy MA, Henry DN, Elguero S, Pickette S, Greenfield M. Accessory and cavitated Uterine Mass with functional endometrium in an adolescent: Diagnosis and laparoscopic excision Technique. *J Pediatr Adolesc Gynecol* 2013; 26: 89-91.
- Paul PG, Chopade G et al. ACUM A rare cause of Severe Dysmenorrhoea in Young Women. *JMIG* 2015; 22: 1300-1303.